

# EXHIBIT R



# VICTORIAN INSTITUTE OF FORENSIC MEDICINE

8 March, 2019

Amber Richards  
Senior Solicitor (for the Crown Solicitor)  
Inquiry into the convictions of Kathleen Megan Folbigg  
Level 2, Industrial Relations Commission  
47 Bridge St  
Sydney  
NSW 2000.

Dear Ms Richards,

Thank you for your letter of 22 February. I responded with a letter dated 26 February (ultimately sent to you on 6 March). Your email of 7 March raised some questions about the 26 February response. After consulting with you, I have consolidated my original response and answers to your questions in an amended and extended version of the 26 February response.

1. Please find enclosed a copy of the email I sent to the VIFM consultants (and a few other trainee pathologists).
2. As you can see, the email was cc'ed to 'dl\_pathconsultants', and therefore everyone received the same email and attachments. (With the exception of Joanna Glengarry, who was a consultant, the named individuals on the email were trainees.)
3. As you can see on the email, attached were 13 micrographs (labelled Slide 1,2,3,4,6,7,8,10,11,12,13,14,15 – each with the suffix .jpg). These are the numbers 1-15 but without 5 and 9. Thus there were 13 images sent to all the pathologists.
  - Slides 1 and 2 are substantially overlapping images of the same field,
  - Slides 7 and 8 are images of the same field. Slide 10 is a higher power view of the central area of slide 7/8. Slides 11 and 12 are the same as each other and are a higher power view again of 7/8/10.
  - Slides 3,4,6,13,14,15 are different to the above and to each other

The 13 slides therefore represent 8 different fields.

4. I have attached micrographs at Appendix 4 of my report. The index at the front of the report has this correctly, but as you point out it has escaped my proof reading in the body of the report itself. The reference on P77 to Appendix 3 should indeed be a reference to Appendix 4. Thank you for the correction.

5. Appendix 4 in fact includes 10 micrographs. Each of the 5 pages of the Appendix has 2 photomicrographs. You can see at the middle of each page a white line on the right which is continuous with a division between two different images. On three of the 5 pages, the two images are at the same magnification, so if you are not careful you could miss it. On two of the 5 pages the two images are at different magnification and the fact of two images is easily seen.

6. The pages of the appendix are unfortunately not numbered. In my version of my report, which I hope is replicated in everyone else's copy, sequentially, the images are of:

- i. Slide 2.jpg
- ii. Slide 4.jpg
- iii. Slide 6.jpg
- iv. Slide 1.jpg
- v. Slide 11.jpg (=Slide 12, and is a higher power view of 7/8/10)
- vi. Slide 3.jpg
- vii. Slide 14.jpg
- viii. Slide 15.jpg
- ix. Slide 7.jpg (=Slide 8)
- x. Slide 13.jpg

To put this another way, the images in my report represent the micrographs, or Slides number 1,2,3,4,6,7,11,13,14,15 as sent to the VIFM pathologists. Slides 8, 10, 12 have been omitted. As should be clear from the above, i and iv (ie Slides 2 and 1 respectively) are substantially overlapping views of the same field. Again, this set of 10 micrographs represents 8 different fields

7. I have checked the above order with both

- the copy of my report contained in the circulated folder labelled: "Expert reports relevant to forensic pathology and SIDS/SUDI tender bundle", and
- the copy of my report you sent me electronically in your 7 March email.

In both of these the order is the same as in the list above at 6.

8. I apologise for confusing terminology.


- Photomicrograph: a photograph of something seen through a microscope; sometimes referred to as microphotographs
- Micrograph: Abbreviated form of, and the same as, photomicrograph
- Slide: Depending on the context: a microscope slide containing the tissue being examined; or the resulting micrograph (as in photographic slide)
- Image: A broad term applicable to different forms of photographic material eg photographs, micrographs, slides, videos etc
- Field: the field of view looking through the microscope (or through a camera)
- Block: (Unrelated to photography), the wax block containing the small sample of tissue (often about the size of a 10 cent piece) removed at autopsy which is then

thinly cut, the resulting slice being placed on a glass slide, processed and coloured with dyes so that it can be viewed under the microscope.

9. Please find attached the reply from Dr Michael Burke. It is an email dated 28/11/2014 with a reply which also incorporates an earlier reply dated 09/09/2014.

I hope this all makes sense. Please get back to me if there are any problems.

Yours sincerely,

A handwritten signature in black ink that reads "Stephen Cordner, 8 Nov, 2014". The signature is written in a cursive style.

Stephen Cordner

Professor of Forensic Pathology (International), Monash University  
Head, International Programmes, Victorian Institute of Forensic Medicine.

Encs x 2

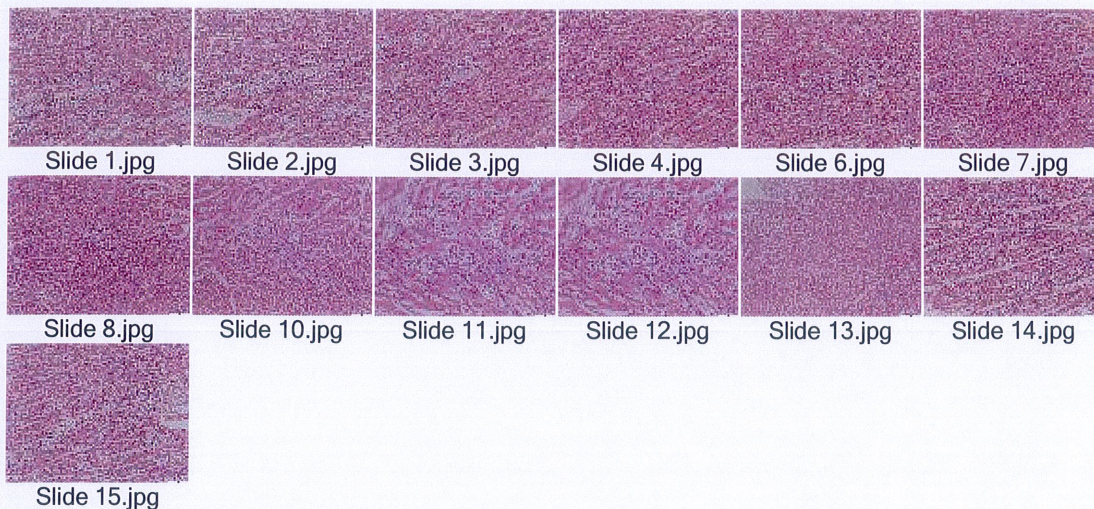
Email dated 04/09/2014 to dl\_pathconsultants (et al) from Stephen Cordner  
Email dated 28/11/2014 to Stephen Cordner from Michael Burke.



## Myocarditis vs unascertained cause of death in a 19 month old girl.

dl\_pathconsultants, Victoria Francis,  
Stephen Cordner to: Greg Young, Joanna Glengarry, Diana  
Jaravaza, Ravindra Samaranayake

04/09/2014 04:43 PM



This girl was 19 months old when she died. She had had a runny nose for a couple of days. She was fed at 7am, playing normally at about 11 am. She then had a sleep, and when mother went to check on her around midday, she was not breathing.

Pathologist gave cause of death as unascertained. Apart from myocarditis, which the pathologist reported as being present, the autopsy was negative.

I would be happy with myocarditis as the cause of death.

Any comments on this, or on the myocarditis itself.

Would appreciate feedback.

Cheers

Stephen



### Stephen Cordner

Head, International Programmes | Victorian Institute of Forensic Medicine | [www.vifm.org](http://www.vifm.org)  
Professor of Forensic Pathology (International) | Monash University | [www.monash.edu](http://www.monash.edu)  
57 - 83 Kavanagh Street, Southbank, Victoria, 3006, Australia  
Tel: +613 9684 4307 | Mobile: +61 418 815 766 | Fax: +613 9682 7353  
[stephen.cordner@vifm.org](mailto:stephen.cordner@vifm.org)

Re: Myocarditis vs unascertained cause of death in a 19 month old girl.

Michael Burke

to:

Stephen Cordner

28/11/2014 11:52 AM

Hide Details

From: Michael Burke/VIFM

To: Stephen Cordner/VIFM

Hi prof, had to step out for a little while. My recollection if your case is that I would have had no hesitation in giving myocarditis as the cause of death. Cheers, Michael

Sent from my iPhone

On 27 Nov 2014, at 9:47 pm, "Stephen Cordner" <[stephen.cordner@vifm.org](mailto:stephen.cordner@vifm.org)> wrote:

Dear Michael,

I wonder if you can cast your mind back to this and let me know whether in the circs as described you would heve been happy or not to give the cod as myocarditis.

Many thanks.

S

-----Michael Burke/VIFM wrote: -----

To: Stephen Cordner/VIFM

From: Michael Burke/VIFM

Date: 09/09/2014 07:48AM

Subject: Re: Fw: Myocarditis vs unascertained cause of death in a 19 month old girl.

Good morning,

It cannot be anything else other than myocarditis,

Regards,

Michael

\* Stephen Cordner---08/09/2014 03:50:06 PM---Dear All, I have had some feedback from some of you, but not quite half. Would appreciate a response

From: Stephen Cordner/VIFM

To: dl\_pathconsultants

Cc: Greg Young/VIFM@VIFM, Victoria Francis/VIFM@VIFM, Joanna

Glengarry/VIFM@VIFM

Date: 08/09/2014 03:50 PM

Subject: Fw: Myocarditis vs unascertained cause of death in a 19 month old girl.

Dear All,

I have had some feedback from some of you, but not quite half. Would appreciate a response if at all possible. Many thanks.

Stephen

<Image.1417085262906.gif>

**Stephen Cordner**

**Head, International Programmes** | | Victorian

Institute of Forensic Medicine | [www.vifm.org](http://www.vifm.org)

**Professor of Forensic Pathology**

**(International)** | Monash University |

[www.monash.edu](http://www.monash.edu)

57 - 83 Kavanagh Street, Southbank, Victoria, 3006,  
Australia

Tel: +613 9684 4307 | Mobile: +61 418 815 766 |

Fax: +613 9682 7353

[stephen.cordner@vifm.org](mailto:stephen.cordner@vifm.org)

----- Forwarded by Stephen Cordner/VIFM on 08/09/2014 03:48 PM -----

From: Stephen Cordner/VIFM

To: dl\_pathconsultants, Victoria Francis/VIFM@VIFM, Greg Young/VIFM@VIFM,

Joanna Glengarry/VIFM@VIFM, Diana Jaravaza/VIFM@VIFM, Ravindra

Samaranayake/VIFM@VIFM

Date: 04/09/2014 04:43 PM

Subject: Myocarditis vs unascertained cause of death in a 19 month old girl.

[attachment "Slide 1.jpg" deleted by Michael Burke/VIFM] [attachment "Slide 2.jpg" deleted by Michael Burke/VIFM] [attachment "Slide 3.jpg" deleted by Michael Burke/VIFM] [attachment "Slide 4.jpg" deleted by Michael Burke/VIFM] [attachment "Slide 6.jpg" deleted by Michael Burke/VIFM] [attachment "Slide 7.jpg" deleted by Michael Burke/VIFM] [attachment "Slide 8.jpg" deleted by Michael Burke/VIFM] [attachment "Slide 10.jpg" deleted by Michael Burke/VIFM] [attachment "Slide 11.jpg" deleted by Michael Burke/VIFM] [attachment "Slide 12.jpg" deleted by Michael Burke/VIFM] [attachment "Slide 13.jpg" deleted by Michael Burke/VIFM] [attachment "Slide 14.jpg" deleted by Michael Burke/VIFM] [attachment "Slide 15.jpg" deleted by Michael Burke/VIFM]

This girl was 19 months old when she died. She had had a runny nose for a couple of days. She was fed at 7am, playing normally at about 11 am. She then had a sleep, and when mother went to check on her around midday, she was not breathing.

Pathologist gave cause of death as unascertained. Apart from myocarditis, which the pathologist reported as being present, the autopsy was negative.

I would be happy with myocarditis as the cause of death.

Any comments on this, or on the myocarditis itself.

Would appreciate feedback.

Cheers

Stephen

<Image.1417085262906.gif>

**Stephen Cordner**

**Head, International Programmes** | | Victorian

Institute of Forensic Medicine | [www.vifm.org](http://www.vifm.org)

**Professor of Forensic Pathology**

**(International)** | Monash University |

[www.monash.edu](http://www.monash.edu)

57 - 83 Kavanagh Street, Southbank, Victoria, 3006,  
Australia

Tel: +613 9684 4307 | Mobile: +61 418 815 766 |

Fax: +613 9682 7353

[stephen.cordner@vifm.org](mailto:stephen.cordner@vifm.org)

<Image.1417085262907.gif>



## **Inquiry into the convictions of Kathleen Megan Folbigg**

22 February 2019

Professor Stephen Cordner  
Victorian Institute of Forensic Medicine  
57-83 Kavanagh Street  
SOUTHBANK VIC 3006

**By email: [stephen.cordner@vifm.org](mailto:stephen.cordner@vifm.org)**

**cc: [stuart.gray@cardillograypartners.com.au](mailto:stuart.gray@cardillograypartners.com.au); [jeremy.morris@stjames.net.au](mailto:jeremy.morris@stjames.net.au);  
[rcavanagh@sirowendixon.com.au](mailto:rcavanagh@sirowendixon.com.au); [rhanee@cardillograypartners.com.au](mailto:rhanee@cardillograypartners.com.au);  
[ian.fraser@fjc.net.au](mailto:ian.fraser@fjc.net.au); [blyon@doh.health.nsw.gov.au](mailto:blyon@doh.health.nsw.gov.au);  
[tony.mineo@avant.org.au](mailto:tony.mineo@avant.org.au);  
[paulina.moncrieff@nortonrosefulbright.com](mailto:paulina.moncrieff@nortonrosefulbright.com);  
[mary-kate.rankin@nortonrosefulbright.com](mailto:mary-kate.rankin@nortonrosefulbright.com);  
[jduflou@forensicmedicine.com.au](mailto:jduflou@forensicmedicine.com.au)**

Dear Professor Cordner

### **Material provided to experts from Victorian Institute of Forensic Medicine**

We refer to our letter to Mr Gray of yesterday's date on which you were copied. As explained in that letter, we note that at p 77 of your expert report you refer to circulating an email to ten consultant forensic pathology colleagues at the Victorian Institute of Forensic Medicine ("VIFM"), together with a number of photomicrographs, which you stated were annexed to Appendix 3 of the report.

Appendix 3 appears to be intended to be a reference to Appendix 4 to your report. Appendix 4, titled "Photomicrographs of Laura's heart", contains five images, but Appendix 3 is an academic article. We would be grateful if you could confirm the reference to Appendix 3 on p 77 should therefore be a reference to Appendix 4.

As also noted in our letter to Mr Gray, the expert reports prepared at Mr Gray's instruction by experts from VIFM do not make clear which photomicrographs were provided to each expert together with your initial email. In particular, some experts state they received 13 photomicrographs while others report receiving 15 photomicrographs. Please advise what was provided to each expert together with your email and how these relate to the five images included at Appendix 4 to your report. Please also confirm the response you received to your email from Dr Michael Burke, as this is not clear from his expert report.

### **Inquiry into the convictions of Kathleen Megan Folbigg**

Level 2 | Industrial Relations Commission | 47 Bridge Street | SYDNEY NSW 2000


**T** (02) 8759 0793 | **E** [folbigg.inquiry@justice.nsw.gov.au](mailto:folbigg.inquiry@justice.nsw.gov.au)

**W** <https://www.folbigginquiry.justice.nsw.gov.au>



If you have any questions, please do not hesitate to get in touch with Amber Richards on (02) 8759 0793 or [amber.richards@cso.nsw.gov.au](mailto:amber.richards@cso.nsw.gov.au).

Kind regards



Amber Richards  
Senior Solicitor  
**for Crown Solicitor**